

Nerve injury: Classification, clinical assessment, investigation, and management

Tim Hems¹

¹The Victoria Infirmary, NHS Greater Glasgow and Clyde, Glasgow, United Kingdom

Abstract

Seddon's classification of nerve injuries into three categories, neurapraxia, axonotmesis, and neurotmesis provides a basis for assessment, prognosis, and management. The clinical history and examination are paramount in assessing the extent and severity of nerve injury. Investigations, including neurophysiology testing and imaging with MRI or ultrasound, may give extra diagnostic information. Open nerve injuries require exploration and repair within a few days. Closed stretch or compression injuries may warrant early exploration or can be managed expectantly depending on the probability that nerves are disrupted.

Classification of nerve injuries

Classification of nerve injuries is useful in understanding their pathological basis, making decisions on management, and predicting the prognosis for recovery. Seddon [1] described a classification of localized injuries to peripheral nerves after study of large numbers of casualties during the second world war, which is still widely used.

- *Neurapraxia*
- *Axonotmesis*
- *Neurotmesis*

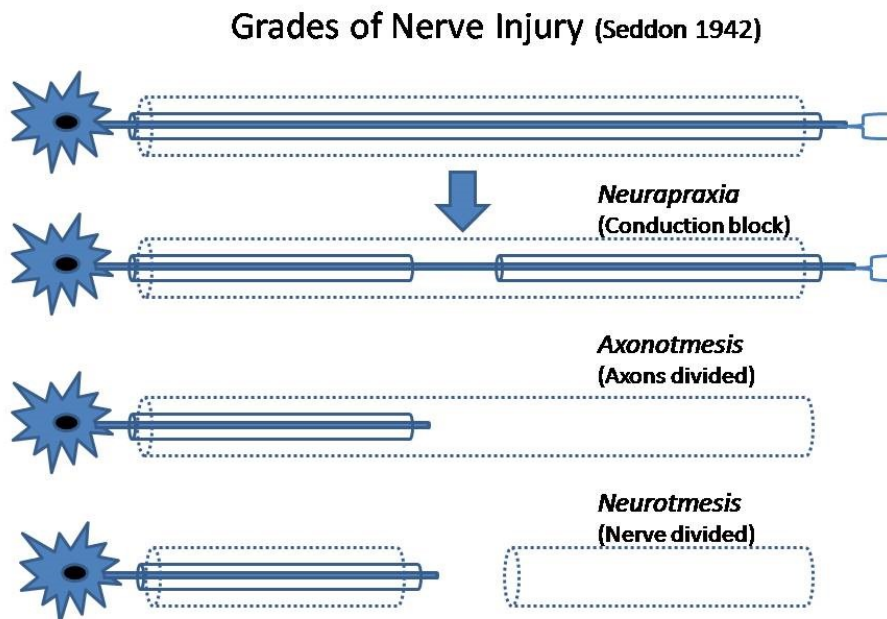


Figure 1: Diagram outlining the grades of injury described in Seddon's classification

Neurapraxia (nerve not working)



Neurapraxia is the mildest injury to a nerve, caused by transient compression or stretch. Loss of nerve function results from conduction block. Paralysis of muscles innervated by the nerve is complete but some sensation may be preserved. Autonomic function may also be preserved. This type of injury will recover completely providing the cause, for example, ongoing compression, is removed. Recovery does not follow a proximal to distal progression as occurs with axon regeneration. As long as there is no ongoing insult cases of neurapraxia can be managed without operation.

Axonotmesis (axons divided)

Axonotmesis results from a more severe blunt injury to a nerve. This is sufficient to cause axon degeneration but the connective tissue layers of the nerve including the endoneurial tubes remain intact. Radial nerve injury associated with fracture of the humeral shaft is often an axonotmesis. Clinical examination reveals complete loss of motor, sensory, and autonomic function. Since axons distal to the site of injury have undergone Wallerian degeneration conduction is lost both at and distal to the site of injury. Providing the cause is removed, uncomplicated regeneration of axons occurs along the same pathway will occur, with recovery of function progressing from proximal to distal. Tinel's sign can be elicited initially at the site of the injury and will advance distally over time. There is usually near normal recovery.

Neurotmesis (whole nerve divided)

Neurotmesis is the situation where a nerve is completely divided or so badly disorganized that recovery cannot occur. All the connective tissue layers of the nerve as well as the axons are disrupted. There is axon degeneration distal to the injury. Neurotmesis may be caused by laceration or high energy traction injuries sufficient to rupture the nerve. In addition injection of noxious drugs or ischaemia can destroy a nerve. Recovery can only occur after appropriate surgical repair of the nerve and relies on axonal regeneration. Because disruption and mixing of fibres at the site of the repair results in failure of correct distal connections, recovery is never perfect. In general the outcome is worse after repair of a nerve ruptured by severe traction rather than direct repair of a clean laceration.

It should be emphasized that the findings on clinical examination and neurophysiology assessment may be the same for axonotmesis and neurotmesis, yet there is a clear difference in prognosis and management.

Limitations of Seddon's classification

Seddon's classification doesn't distinguish between all grades of intraneural damage. Lesions classified as axonotmesis have been observed to have variable recovery. This is because variable degrees of damage to the connective tissue layers of the nerve, including the endoneurium and perineurium, as well as disruption of the axons are possible without loss of continuity of the nerve trunk.

Extracted Table: Table 1

Sunderland's classification

In 1951 Sunderland [2] described five degrees of injury to a nerve (Table 1). This is based on increasing anatomical disruption of the nerve trunk and distinguishes injuries where the nerve trunk is in continuity but there is damage to endoneurium and perineurium. Sunderland's observations suggested that there is likely to be recovery, although variable, in cases of 3rd degree injury where the endoneurial tubes are damaged but perineurium is intact, but that useful recovery is unlikely for 4th degree injuries where perineurium is disrupted. This distinction is useful when exploring a nervedamaged by blunt trauma. If fascicles are found to be in-continuity, then the injury is not worse than 3rd degree and spontaneous recovery may occur, while fourth degree injuries require repair.

McKinnon and Dellon [3] added to the classification suggesting a 6th degree injury. This is a situation, which is not uncommon, where there are variable degrees of injury to different parts of a nerve trunk. There is a mixed pattern of recovery.

Overview of classification

The distinction between cases of conduction block (non-degenerative lesions) and those causing axon degeneration is important in prognosis. However, this can be difficult to diagnose early after an injury. The most important issue influencing management is the difference between lesions where the nerve is in-contiguity (neurapraxia and axonotmesis) and those where recovery will not occur without surgical repair (neurotmesis). In cases of loss of continuity the classifications do not distinguish between tidy lacerations and injuries where a length of nerve is disrupted.

Clinical assessment of nerve injuries

Clinical assessment remains the most important step in diagnosis of nerve injury or other nerve conditions. The mechanism of injury, in particular sharp or blunt trauma, should be established. In the case of blunt trauma high energy and open injuries tend to be associated with more severe nerve injuries. It is important to check whether the neurological deficit was present immediately after the injury or had later onset. Associated injuries to the skeleton and soft tissue both at the site of nerve injury and elsewhere should be noted. In addition to checking the loss of function, history should include presence and severity of pain.

Examination of nerve function includes motor power, sensation and autonomic function.

Motor function

Useful information on motor function may be obtained simply by observing the resting position of the hand, with abnormalities such as clawing of the fingers associated with ulnar nerve dysfunction. Muscle bulk should be checked, with wasting of muscles indicating a prolonged denervation. When testing muscle power, the patient should be asked to perform the desired movement while the examiner resists this movement and also palpates either the muscle belly or the tendon of the muscle were being tested. This is particularly important when more than one muscle can perform a movement and help to confirm that individual muscles are functioning.

The most commonly used grading system for muscle power is the Medical Research Council (MRC) system [4] (see table 2). This scale is rather a coarse measure but is easy to apply in the clinical situation. No special equipment is needed.

Table 2: MRC classification of motor nerve dysfunction

Grade	Clinical features
M0	Complete paralysis
M1	Flicker of muscle activity
M2	Power insufficient to overcome gravity
M3	Movement against gravity throughout the range of movement of the joint
M4	Movement against resistance
M4+	Strong movement, but not normal
M5	Normal, full power

Sensory Function

There are different methods of sensory assessment of varying complexity. A simple assessment of touch sensation is whether it is normal, altered, or absent. There is MRC Classification of sensory function (see table 3).

Table 3: MRC classification of sensory nerve dysfunction [4]

Grade	Clinical features
S0	No sensation
S1	Deep pain sensation
S2	Skin touch, pain and thermal sensation, ie. Protective sensation
S3	S2 also with accurate localisation but deficient stereognosis. Cold sensitivity and hypersensitivity are often present.
S3+	Object and texture recognition, but not normal sensation. Good but not normal, two-point discrimination.
S4	Normal sensation

More detailed tests of sensation include:

1. Localisation
2. Two point discrimination (2PD)
3. Threshold
4. Temperature
5. Vibration

Two point discrimination is a test which can be easily carried out clinically [5]. It is a measure of tactile recognition. The minimum width between two points touching the skin, which can be perceived as separate, is measured either using a calibrated device or a U-shaped piece of wire, which can be made from a paper clip. Normal two point discrimination is approximately 4 mm on the pulps of the fingers (Figure 2). It is an objective measurement which is particularly useful for assessing sensation in the hand after injury. Normal two point discrimination indicates continuity of a nerve. It is less useful in assessing nerve recovery since it rarely recovers well after repair of a nerve.




Figure 2: Testing two point discrimination on the pulps of fingers.

Measures of touch threshold include Semmes Weinstein Monofilaments. These calibrated filaments (see figure 3) are applied to the skin and allow a measure of the minimum pressure which can be perceived.




Figure 3: Measurement of sensory thresholds using Semmes Weinstein monofilaments.

The full set of filaments is 20 but often a smaller set of 5 is used. There is usually colour coding with green being normal, blue indicating diminished touch, purple indicating diminished protective sensation and red loss of protective sensation (see table 4).

Table 4: Semmes-Weinstein monofilaments (sensory thresholds)

Filament	Interpretation	Force (grams)
1.65–2.83 (green)	Normal	0.008–0.08
3.22–3.61 (blue)	Diminished light touch	0.172–0.217
3.84–4.31 (purple)	Diminished protective sensation	0.445–2.35
4.56 (red)	Loss of protective sensation	4.19
6.65 (red)	Deep pressure sensation	279.4

Autonomic function

Autonomic function can be checked by assessing sweating. Loss of sweating occurs if there is loss of autonomic function. This is an objective sign of nerve function which doesn't depend on co-operation of the patient. It is useful on assessment after acute nerve injuries. For digital nerves a simple assessment of sweating is to run a plastic pen along each order of the fingers. If sweating is absent the skin will be smoother and drier.

Examination of individual nerves innervating the hand

Radial nerve

When examining radial nerve function in the forearm, wrist extension should be tested with the fingers flexed and palpating the wrist extensor muscles on the dorsum of the wrist. The radial wrist extensors – ECRL (M. extensor radialis longus) and ECRB (M. extensor radialis brevis) – are most easily felt. While testing finger extension the wrist should be held in extension in order to eliminate the tenodesis effect which causes extension of the fingers when flexing the wrist (Figure 4). The tendons should be palpated and observed on the dorsum of the hand and wrist. M extensor pollicis longus (EPL) produces extension of the whole thumb column. Sensation is tested in the autonomous area of the radial nerve on the dorsum of the 1st web space.

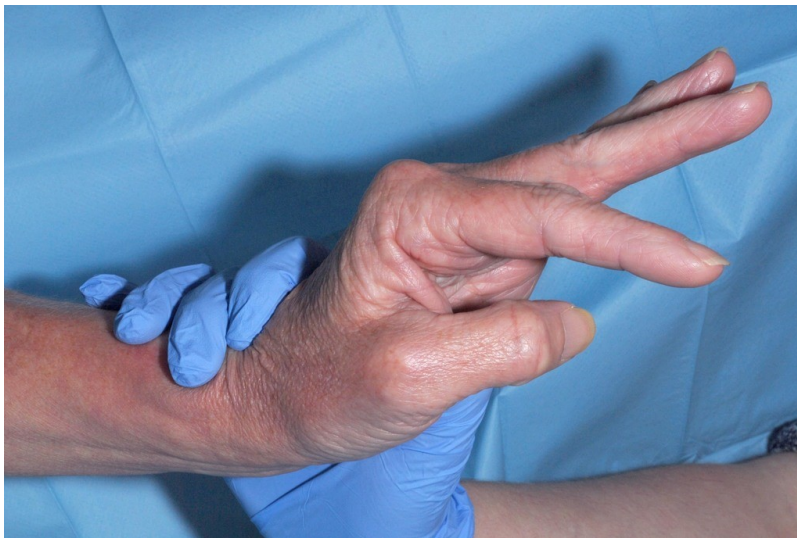

Figure 4: Patient with partial posterior interosseous nerve palsy. When assessing radial nerve function, finger extension should be tested with the wrist held in extension.

Median nerve

Assessment of median nerve motor function should include M. flexor carpi radialis (FCR) as well as FPL (M. flexor pollicis longus), FDP (M. flexor digitorum profundus) to each finger, and FDS (M. flexor

digitorum superficialis). FDS muscle function can be tested in a similar way to the integrity of FDS tendons, by holding the other fingers in extension while asking the patient to actively flex the finger at the PIP (proximal interphalangeal) joint. Thenar muscles, in particular abductor pollicis brevis, are tested by abduction of the thumb from the palm. Sensation is tested on the pulps of the thumb, index, middle and radial half of the ring fingers. It is important to distinguish the level of injury to the median nerve, either at the wrist or more proximally. If there are signs of more proximal dysfunction whether the whole median nerve is affected or just the anterior interosseous nerve should be established.

Ulnar nerve

Ulnar nerve innervation of forearm muscles can be checked by testing FCU (M. flexor carpi ulnaris) and FDP to the little finger. However, the main motor function of the ulnar nerve is innervation of the intrinsic muscles of the hand. Loss of these causes clawing of the ring and little fingers. The most specific test for the interossei muscles is finger adduction. Some degree of abduction of the fingers can be produced by the long finger extensors. It should be remembered that the fingers can only be abducted with the MCP (metacarpophalangeal) joint in extension. Therefore a patient with radial nerve palsy will not be able to abduct the fingers normally.

A number of specific tests have been described for the ulnar innervated intrinsic muscles of the hand. Froment [6] described the sign of increased flexion of the IP joint on thumb during lateral pinch movements. While performing this test it is also useful to palpate the contraction in the first dorsal interosseous and adductor pollicis (Figure 5). The power of finger adduction can be compared between the hands by asking the patient to hold a sheet of paper between the fingers. The power of abduction of the little fingers can be compared by asking the patient to abduct his fingers and push one hand against the other hand. Sensation is tested in the little finger and on the ulnar side of the ring finger. While many pathologies will affect the whole of the ulnar nerve occasionally only part of the nerve is affected, for example isolated injury or compression affecting the deep motor branch in the hand.



Figure 5: Examination of ulnar nerve function. When looking for Froment's sign, it is useful to palpate the 1st dorsal interosseous and adductor pollicis muscles while the patient performs lateral pinch.

Investigations

Neurophysiology

After careful clinical assessment neurophysiological testing may give additional information on a nerve injury. Even when a nerve is divided the axons in the distal segment continue to conduct for a few days. It may be nearly 2 weeks before conduction ceases completely and therefore reliable results can be obtained on testing. Therefore neurophysiology is not applicable in open injuries or other injuries requiring very early surgical exploration. As well as the equipment for nerve stimulation and recording,

experience is needed to carry out tests and interpret the results. The main types of test performed are (See also [Basics in clinical neurophysiology: Nerve conduction studies and needle electromyography in nerve entrapment syndromes](#)):

- Motor and sensory nerve conduction studies
- Electromyography (EMG)

In general the neurophysiology tests can distinguish between injuries where axons have not degenerated (neurapraxia) and those where axons have degenerated distally (axonotmesis and neurotmesis) (see [table 1](#)). If axonotmesis has affected all the fibres in a nerve then the findings will be indistinguishable neurotmesis. However, if there is a mixed lesion with some fibres intact detection of these will imply the nerve trunk has not been disrupted.

Magnetic Resonance Imaging (MRI)

Normal nerves can be visualised on MRI although their signal characteristics are not distinct from other tissues. A technique called magnetic resonance neurography, which enhances neural tissue on images, was reported by Filler [\[7\]](#). Although early reported results were promising for defining nerve pathology, continuing experience suggests that it is difficult to obtain consistent results using standard clinical MR scanners. In the zone of injury signals are affected by oedema and haemorrhage in the surrounding tissues. MRI has proved effective in imaging peripheral nerve tumours [\[8\]](#). It is also useful in assessment of brachial plexus injuries where avulsion of nerve roots can be defined [\[9\]](#).

In addition to imaging the nerves themselves, information may be obtained from MRI of muscle innervated by damaged nerves. On T2 and STIR images changes may be seen in denervated muscle as early as two weeks after injury [\[10\]](#). The exact relationship between severity of nerve injury and the early signal changes in muscles seen on MRI is not clear. More prolonged denervation of muscle leads to wasting and fatty infiltration which can be seen on T1 weighted MR images [\[11\]](#) (Figure 6).

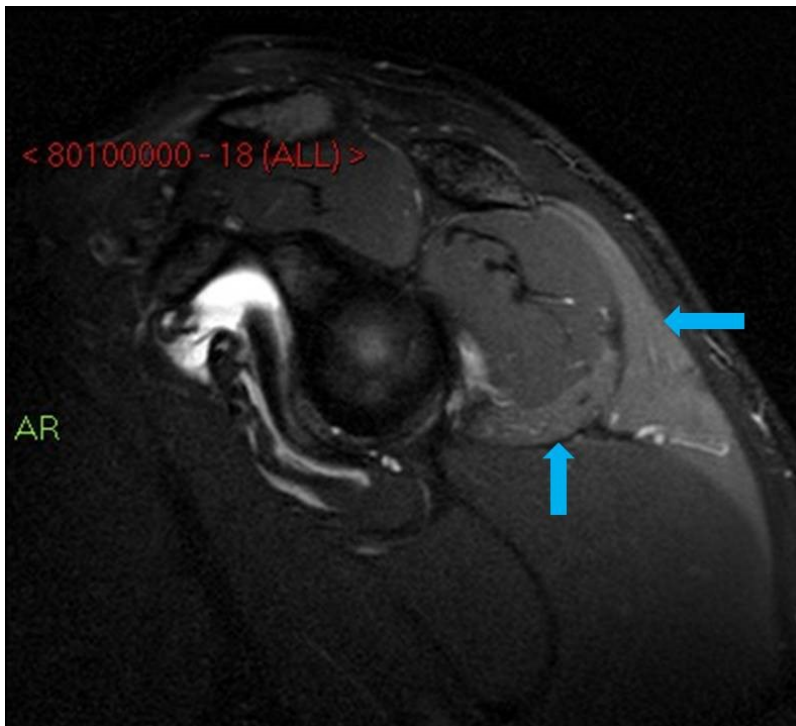


Figure 6: Sagittal T2 weighted magnetic resonance image of the shoulder showing increased signal in deltoid and teres minor as a result of axillary nerve injury.

Ultrasound

Modern ultrasound scanners have improved to the extent that resolution is now greater than MRI. Ultrasound is being used increasingly to examine nerves damaged by closed trauma. It may be able to confirm continuity of a nerve, or diagnose rupture or entrapment, for example, in a fracture. Fascicular

disruption within a nerve trunk may be visualised. Use of ultrasound to examine the radial nerve injured in an association with fractures of the humerus been reported [12] and for diagnosis of median nerve entrapment in the forearm [13]. However, ultrasound is operator dependent and requires experience for optimal interpretation.

Principles of management of nerve injury

While the classifications of nerve injury provide a basis for prognosis and management, in reality it can be difficult to diagnose the grade of injury to a nerve in the early stages. The situation may only become clear in retrospect. Therefore a practical approach to management is recommended. It is useful to divide injuries into those which are open and closed.

Open injuries

When there is evidence of loss of function in a nerve associated with a wound, then in most circumstances exploration of the wound and the affected nerve should be carried out. The only exception to this would be, if expert assessment indicates that the patient is unlikely to benefit from repair of the nerve or if the patient is unfit for operation. Otherwise the wound should be explored as soon as appropriate surgical expertise is available. Uncertainty can occur when a nerve is partly divided since some function will be preserved. Therefore lacerations associated with any neurological deficit should be explored on the assumption that affected nerves are either partly or completely divided rather than assuming that there is some form of lesion in-continuity.

Usually nerve repair should be carried out early at the same time as other injured structures. Therefore fracture fixation, tendon repairs and skin closure is carried out simultaneously, providing adequate vascularised skin and cover can be provided. Full thickness vascularised skin cover is necessary over a nerve repair rather than split skin graft.

Closed injuries

When a nerve has been injured as a result of blunt trauma there is likely to be more uncertainty regarding the grade of injury. In general an assessment should be made of the probability that a nerve has been disrupted or is under continuing compression (see next section). If the injury has been caused by high energy trauma then the chance of disruption of the nerve is higher and early exploration should be considered. If operation is required in any case, for example, for fracture fixation, then the opportunity should not be missed to explore damaged nerves and confirm continuity. Early exploration is best carried out within the first 2 weeks following injury. If there has been lower energy trauma and a lesion in-continuity seems likely then expectant management may be pursued. However, progress of nerve recovery should be monitored carefully looking for return of muscle function and an advancing Tinel's sign. If there is no improvement by 2 to 3 months from injury then surgical exploration should be considered. Urgent neurophysiology assessment and imaging may help at this stage.

Acute nerve compression

Nerves may be compressed by displaced fragments of fractures, dislocation of joints, or expanding hematoma. The onset of loss of nerve function may be delayed after the injury although this may be difficult to ascertain. Typically there is severe pain associated with the nerve palsy. This situation requires urgent management with reduction of fractures and dislocations. If closed reduction does not relieve the situation then open reduction with exploration of the affected nerves should be performed. If there is suspicion of arterial injury, for example, false aneurysm, then angiography should be arranged. Haematoma with sufficient pressure to cause nerve compression is likely to have been caused by arterial haemorrhage. Drainage of the haematoma and vessel repair is required as an emergency. There are specific anatomical sites when nerves are particularly prone to compression. For example, at the wrist, injury to the distal radius or carpus may result in a compression of the median nerve within the carpal canal. In this, and other similar situations, decompression of the nerve within hours is indicated otherwise an injury that started as a conduction block will progress to cause axonal degeneration (see section on conduction block).

Nerve injury associated with medical and surgical procedures

A nerve palsy occurring after a medical or surgical procedure represents a particularly difficult management situation. This is an unfortunate and sometimes disastrous complication of treatment. It is important to examine the function of nerves related to a surgical procedure and document the findings before and afterwards. In reality it can be difficult to assess nerve function accurately when patients present with acute limb trauma particularly if their conscious level is compromised. If a patient is found to have a new loss of nerve function after a procedure then a prompt, careful and objective assessment needs to be made. Since the clinician who has performed the procedure may have an emotional attachment to the situation, it is often best to involve another clinician, if possible, someone who has specialist experience in the management of peripheral nerve injuries. Consideration should be given to exploring the damaged nerve at an early stage taking into account the following factors.

1. The events during the procedure should be reviewed to check whether the nerve was identified and what the likely mechanism of injury is, including laceration or compression.
2. Whether the nerve palsy was present immediately after the procedure or developed after a delay. The patient can usually give a useful account of events.
3. If there is a possibility that the nerve is being subjected to continuing compression, by haematoma or an implant then urgent re-operation should be carried out. In this situation the nerve palsy is usually associated with severe pain.
4. Urgent investigations, including ultrasound, MRI, and neurophysiology may be helpful, but as with other nerve injuries the findings on neurophysiology testing cannot be relied upon until 2 to 3 weeks after injury.
5. The risks and benefits of carrying out a second procedure, including the patient's general condition, the risk of infection, and whether repair of the affected nerve is likely to lead to useful functional recovery.

In general, there should be a low threshold for re-exploration of the affected nerve to establish that it is in continuity and free of compression. In some cases this will reassure the patient and the surgeon that recovery of the nerve is likely. If the nerve is found to be divided then early repair can be carried out giving the best chance of recovery.

References

1. Seddon HJ. A Classification of Nerve Injuries. *Br Med J*. 1942 Aug 29;2(4260):237-9. DOI: [10.1136/bmj.2.4260.237](https://doi.org/10.1136/bmj.2.4260.237)
2. Sunderland S. A classification of peripheral nerve injuries producing loss of function. *Brain*. 1951 Dec;74(4):491-516. DOI: [10.1093/brain/74.4.491](https://doi.org/10.1093/brain/74.4.491)
3. Mackinnon SE, Dellon AL. *Surgery of the Peripheral Nerve*. New York: Thieme; 1988. p. 35-63.
4. Seddon HJ. *Peripheral nerve injuries: Medical Research Council special report series no. 282*. London: Her Majesty's Stationary Office; 1954.
5. Lundborg G, Rosén B. The two-point discrimination test--time for a re-appraisal? *J Hand Surg Br*. 2004 Oct;29(5):418-22. DOI: [10.1016/J.JHSB.2004.02.008](https://doi.org/10.1016/J.JHSB.2004.02.008)
6. Froment J. La préhension dans les paralysies du nerf cubital et le signe du pouce. *Presse med*. 1915;23:409.
7. Filler AG, Kliot M, Howe FA, Hayes CE, Saunders DE, Goodkin R, Bell BA, Winn HR, Griffiths JR, Tsuruda JS. Application of magnetic resonance neurography in the evaluation of patients with peripheral nerve pathology. *J Neurosurg*. 1996 Aug;85(2):299-309. DOI: [10.3171/jns.1996.85.2.0299](https://doi.org/10.3171/jns.1996.85.2.0299)
8. Hems TE, Burge PD, Wilson DJ. The role of magnetic resonance imaging in the management of peripheral nerve tumours. *J Hand Surg Br*. 1997 Feb;22(1):57-60. DOI: [10.1016/S0266-7681\(97\)80018-6](https://doi.org/10.1016/S0266-7681(97)80018-6)
9. Hems TE, Birch R, Carlstedt T. The role of magnetic resonance imaging in the management of traction injuries to the adult brachial plexus. *J Hand Surg Br*. 1999 Oct;24(5):550-5. DOI: [10.1054/JHSB.1999.0234](https://doi.org/10.1054/JHSB.1999.0234)
10. Uetani M, Hayashi K, Matsunaga N, Imamura K, Ito N. Denervated skeletal muscle: MR imaging. Work in progress. *Radiology*. 1993 Nov;189(2):511-5. DOI: [10.1148/radiology.189.2.8210383](https://doi.org/10.1148/radiology.189.2.8210383)
11. Fleckenstein JL, Watumull D, Conner KE, Ezaki M, Greenlee RG Jr, Bryan WW, Chason DP, Parkey RW, Peshock RM, Purdy PD. Denervated human skeletal muscle: MR imaging evaluation. *Radiology*. 1993 Apr;187(1):213-8. DOI: [10.1148/radiology.187.1.8451416](https://doi.org/10.1148/radiology.187.1.8451416)
12. Bodner G, Buchberger W, Schocke M, Bale R, Huber B, Harpf C, Gassner E, Jaschke W. Radial nerve palsy associated with humeral shaft fracture: evaluation with US--initial experience.

Radiology. 2001 Jun;219(3):811-6. DOI: [10.1148/radiology.219.3.r01jn09811](https://doi.org/10.1148/radiology.219.3.r01jn09811)

13. Ginn SD, Cartwright MS, Chloros GD, Walker FO, Yoon JS, Brown ME, Wiesler ER. Ultrasound in the diagnosis of a median neuropathy in the forearm: case report. J Brachial Plex Peripher Nerve Inj. 2007 Dec 4;2:23. DOI: [10.1186/1749-7221-2-23](https://doi.org/10.1186/1749-7221-2-23)

Corresponding authors: Tim Hems, Queen Elizabeth University Hospital, Orthopaedic Surgery Glasgow, United Kingdom, E-mail: t.e.j.hems@doctors.org.uk

Citation note: Hems T. Nerve injury: Classification, clinical assessment, investigation, and management. Version 2016-04-28. In: Handchirurgie Weltweit e.V., Böttcher R, editors. Living Textbook of Hand Surgery. Cologne: German Medical Science GMS Publishing House; 2014-. DOI: [10.5680/lhhs000030](https://doi.org/10.5680/lhhs000030)

Copyright: © 2024 Tim Hems

This is an Open Access publication distributed under the terms of the Creative Commons Attribution-ShareAlike 4.0 International License. See license information at <https://creativecommons.org/licenses/by-sa/4.0/>